A Retrospective Case Series Analysis of Patients Undergoing Chronic Wound Treatment Using Skin Grafts Made from a Recently Introduced Epidermal Harvesting System

Scott Gorenstein, MD[1]; Paul Ambrose, PA-S[2]; Tyler Ferraro, MS, PA-C[2]; Julie DiGregorio, CCRP[1]; Christina Ventura-DiPersia, MPH[2]

[1]Winthrop University Hospital, Wound Healing & Hyperbaric Medicine Center, Mineola, NY; [2]Hofstra Northwell School of Graduate Nursing & Physician Assistant Studies, Hempstead, NY

Background

- The burden of chronic wounds in the United States is profound, affecting 6.5 million individuals per year and cost over $25 billion annually in direct and indirect health care costs, as of 2010.[1]
- Treatment and management of chronic wounds often involves an extensive, time-consuming protocol of care that can be burdensome to both providers and patients if it does not result in significant improvement.
- In particular, skin grafting can be painful, invasive, and is often unsuccessful in treating chronic wounds alone.
- In recent years, a new method of epidermal skin harvesting has been introduced. An automated epidermal harvesting system* uses heat and negative pressure to slowly raise small epidermal micrografts in an area of healthy skin that can then be harvested.[2-5]
- This method has been reported to be less painful and invasive than traditional skin grafting.[3,4] While this new approach seems promising, little clinical data exist regarding its use.

Purpose

- To describe a case series with outcomes in a group of 22 patients undergoing chronic wound management using epidermal skin grafts.

Methods

- A retrospective case series analysis was performed via electronic and paper chart review.
- Study population included 25 epidermal graft applications from 22 patients seen between 2014 and 2015 at Winthrop University Hospital's Wound Healing and Hyperbaric Medicine Center (Mineola, NY).
- Variables recorded included: patient age, gender, HgA1c, comorbidities, initial wound size, wound size at each follow-up visit through 4 weeks, duration of graft application, and wound type.
- Fischer's exact test was used to analyze the relationship among multiple variables (e.g. wound type, HgA1c, wounds size at application, graft [harvested using the epidermal harvesting system*], application time, and age) and heal rate; 50% reduction in surface area (cm^2) of the wound was used as a cut off marker for success.

Results

- Three representative cases are shown.
- The patients had mean age of 69.11 years (range= 30-93), and wound types included venous insufficiency ulcers, diabetic foot ulcers, and surgical wounds (**Table 1**).

Results (Cont'd)

Case 1. A 62-year-old female presented with 2 venous leg ulcers to the left anterior leg. Patient comorbidities included: vasculitis, corticosteroid use, and chronic lower leg venous ulcers. The patient underwent surgical debridement and topical cadexmer iodine application prior to grafting. Grafts were secured with a contact layer† and a 3-layer compression bandage.

A. Wounds at presentation (proximal: 2.0 x 0.6cm; distal: 2.5 x 1.5cm)

B. Wounds on day of graft application (proximal: 2.0 x 0.6cm; distal: 2. x 1.5cm)

C. Proximal wound healed 30 days post grafting; distal wound (1.8 x 1.3cm) was progressing

D. Distal wound healed 53 days post grafting

Case 2. A 41-year-old male presented with a re-opened right lateral leg ulcer. Patient comorbidities included: diabetes mellitus, morbid obesity, and venous insufficiency.

A. Wound at presentation

B. Wound (2.0 x 4.0cm) on day of graft application

C. Wound (3.0 x 3.3cm) 4 weeks post grafting

D. Wound fully healed 14 weeks post grafting

Case 3. A 64-year-old male presented with a right heel diabetic foot ulcer. Patient comorbidities included: diabetes mellitus with peripheral neuropathy, left below knee amputation, and venous insufficiency. The patient underwent surgical debridement, total contact casting, hyperbaric oxygen therapy, negative pressure wound therapy (NPWT), and application of an extracellular matrix.

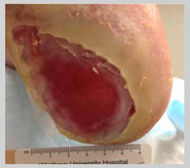

A. Wound at presentation (~4.0 x 3.0cm)

B. Wound after 6 months of wound bed preparation (~4.1 X 1.7cm)

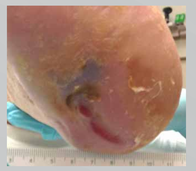

C. Wound 4 weeks post grafting (2.5 x 0.5cm)

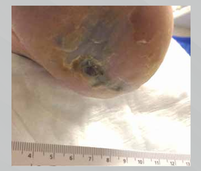

D. Wound fully healed 6 weeks post epidermal grafting

Results (Cont'd)

Table 1. Patient Demographics

Category	n=22 patients, 24 wounds
Age, years (mean ± sd)	69.25 ±15.86
range	30-93
HgA1C, % (mean ± sd)	5.99 ± 1.09
Wound Type	
Venous Insufficiency Ulcer	11 (45.83%)
Diabetic Foot Ulcer	4 (16.67%)
Surgical Wound	4 (16.67%)
Traumatic Wound	2 (8.33%)
Arterial Insufficiency Ulcer	2 (8.33%)
Pressure Ulcer	1 (4.17%)

sd= standard deviation

- Twenty-one of the 24 wounds (84%) exhibited some degree of wound surface area reduction in the study time frame.
- Out of the 25 graft applications, 18 wounds (75%) showed improvement in wound size from 3 to 4 weeks post grafting.
- No Fisher's exact statistical analyses performed were statistically significant.

Conclusions

- Our case series analysis adds to the body of evidence that supports the use of epidermal grafting in a variety of different wound types, as the vast majority (84%) of these wounds showed at least some improvement in wound size during a 4 week time frame.
- In determining when to implement a secondary intervention (e.g. debridement, biological dressings), our research suggests that it may be beneficial to wait 4 weeks post epidermal grafting rather than 3 weeks after initial application as 75% of patients showed improvement from weeks 3 to 4 with an average surface area reduction of 17.3%.
- Areas for future study include a large sample, prospective randomized controlled trial where the epidermal micrograft treatment can be compared to other forms of intervention (e.g. active comparator trial) or no intervention (e.g. placebo trial), with proper analysis of potential effect modifiers that may influence the relationship between wound type and healing rate from this method of treatment.

References

1. Sen CK, Gordillo GM, Roy S, et al. *Wound Repair Regen* 2009;17:763-771.
2. Serena TE. *J Wound Care* 2015;24 (suppl 4):30-34.
3. Osborne S, Schmidt M, Derrick K, et al. *Adv Skin Wound Care* 2015; 28:397-405.
4. Osborne SN, Schmidt MA, Harper. *Adv Skin Wound Care* 2016; 29:57-64.
5. Gabriel A, Sobota RV, Champaneria M. *Surg Technol Int* 2014; 25:55-61.

Acknowledgments

The department of Physician Assistant Studies at the Hofstra Northwell School of Graduate Nursing and Physician Assistant Studies would like to graciously thank the Wound Healing & Hyperbaric Medicine Center of Winthrop University Hospital for allowing this important research to be conducted. The authors also thank ACELITY for the preparation and production of this poster.

Presented at the Symposium on Advanced Wound Care, October 7-9, 2016 Las Vegas, NV

*CELLUTOME™ Epidermal Harvesting System (KCI, an ACELITY Company, San Antonio, TX); †Cutimed® Sorbact® Wound Contact Layer (BSN Medical, Charlotte, NC)